

RUSH: Operative Techniques in Otolaryngology article for proofing (# 0215)

=====

Dear Author,

The proof of your article, to be published by Elsevier in Operative Techniques in Otolaryngology, is available as a "PDF" file at the following URL:

<http://rapidproof.cadmus.com/RapidProof/retrieval/index.jsp>

Login: your e-mail address

Password: ----

The site contains 1 file. You will need to have Adobe Acrobat Reader software to read these files. This is free software and is available for user download at: <http://www.adobe.com/products/acrobat/readstep.html>

After accessing the PDF file, please:

- 1) Carefully proofread the entire article, including any tables, equations, figure legends and references.
- 2) Ensure that your affiliations and address are correct and complete.
- 3) Check that any Greek letter, especially "mu", has translated correctly;
- 4) Verify all scientific notations, drug dosages, and names and locations of manufacturers;
- 5) Be sure permission has been procured for any reprinted material.
- 6) Answer all author queries completely. They are listed on the last page of the proof;

You may choose to list the corrections (including the replies to any queries) in an e-mail and return to me using the "reply" button. Using this option, please refer to the line numbers on the proof. If, for any reason, this is not possible, mark the corrections and any other comments (including replies to questions) on a printout of the PDF file and fax this to Nick DeAngelis (fax #: 717 738 9360), or mail to the address given below.

If you submitted usable colour figures with your article they will appear in colour on the web, at no extra charge, as you can see in the attached PDF proof of your article. In the printed issue, colour reproduction depends on journal policy and whether or not you agree to bear any costs.

Do not attempt to edit the PDF file (including adding post-it type notes).

Within 48 hours, please return the following to the address given below:

- 1) Corrected PDF set of page proofs
- 2) Print quality hard copy figures for corrections if necessary (we CANNOT accept figures on disk at this stage). If your article contains color illustrations and you would like to receive proofs of these illustrations, please contact us within 48 hours.

If you have any problems or questions, please contact me. **PLEASE ALWAYS INCLUDE YOUR ARTICLE NUMBER (0215) WITH ALL CORRESPONDENCE.**

Sincerely,

Nick DeAngelis

Issue Manager, YOTOT

Cadmus

300 West Chestnut Street

Ephrata, PA 17522

Ph: 717 721-2603, Fx: 717 738 9360

E-mail: [deangelisn@cadmus.com](mailto:deangelisn@cadmus.com)



# Tongue suspension suture in obstructive sleep apnea

Kenny P. Pang, FRCSEd, FRCSI(OTO), FAMS(ORL),<sup>a</sup> David J. Terris, MD, FACS<sup>b</sup>

From the <sup>a</sup>Pacific Sleep Centre, Singapore; and the

<sup>b</sup>Department of Otolaryngology-Head and Neck Surgery, Medical College of Georgia, Augusta, Georgia.

## KEYWORDS



Tongue base obstruction is widely acknowledged to be the most difficult level of obstruction to treat in obstructive sleep apnea. A number of methods to correct surgically the tongue base collapse have been proposed. The tongue base suspension suture was introduced as a minimally invasive technique for tongue base stabilization. The technique uses a screw as a bone anchor inserted intraorally into the mandible with an attached Prolene number 1 suture (Ethicon Endo-Surgery, Inc, Cincinnati, OH) that is passed through the tongue. The suture not only provides a sling-like effect in the tongue base but also incorporates into the tongue musculature, imparting rigidity to the airway. This procedure can be performed alone or as part of a multilevel surgical algorithm in the treatment of obstructive sleep apnea. © 2006 Elsevier Inc. All rights reserved.

AQ: 1

Snoring is noisy breathing during sleep and has been considered to be a social “nuisance.” The vibration of the structures in the oral cavity and oropharynx (ie, the soft palate, uvula, tonsils, base of tongue, epiglottis, and pharyngeal walls) cause snoring. Sleep-disordered breathing ranges from simple snoring to obstructive sleep apnea (OSA). It is estimated that in a 30-35-year-old population, 20% of men and 5% of women will snore. Young et al<sup>1</sup> studied 602 state employees with overnight polysomnography, and found that the incidence of sleep-disordered breathing was 24% in men and 9% for women. However, a significant number of individuals with OSA are undiagnosed. It is estimated that up to 93% of females and 82% of males with moderate-to-severe OSA remain undiagnosed.<sup>2</sup> OSA is related to reduced airflow through the upper airway during sleep, caused either by complete or partial upper airway obstruction, or increased upper airway resistance.

Two large prospective studies, the Sleep Heart Health Study<sup>3</sup> and the Wisconsin Sleep Cohort,<sup>4</sup> have shown a link between sleep-disordered breathing and hypertension. Recurrent apnea and hypoxemia have influenced acute thrombotic events,<sup>5,6</sup> atherosclerosis,<sup>7,8</sup> and cerebrovascular accidents (strokes). Studies have shown a higher mortality rate

among patients with cardiovascular disease who also have sleep-disordered breathing.<sup>9,10</sup> The incidence of congestive heart failure<sup>11</sup> has been higher in individuals with sleep-disordered breathing.

The first surgical treatment for OSA was a tracheostomy, described by Kuhlo et al<sup>12</sup> in 1969. This treatment was near uniformly effective in eliminating OSA, but it was poorly tolerated by patients.<sup>13</sup> Complications include wound infection, granulation, stenosis, bleeding, aspiration, fistula formation, and psychologic dependence.

Fujita et al<sup>14</sup> introduced the uvulopalatopharyngoplasty for OSA in 1981. It had been originally described for the treatment of snoring. Since then, there have been many modifications and variations of the technique.

The tongue plays a crucial role in the structural integrity of the upper airway, not only because of its central location in the oral cavity and oropharynx, but also because of its bony attachment. The muscle fibers of the tongue converge and are primarily attached to the posterior surface of the mandible (genial tubercle) in the midline. When the mandible is displaced posteriorly (eg, retrognathia), airway collapse may occur at the base of tongue during sleep. There are a number of surgical techniques that address tongue base collapse, including midline glossectomy or lingual-plasty, genioglossus advancement, radiofrequency reduction of the tongue base, tongue suspension sutures, and hyoid suspension procedures. Swallowing difficulties, speech abnormalities, and breathing and bleeding problems may complicate tongue excisional techniques. The minimally invasive tongue

**Address reprint requests and correspondence:** Kenny Peter Pang, FRCSEd, FRCSI(OTO), FAMS(ORL), Otorhinolaryngology, Director, Pacific Sleep Centre, Paragon Medical Centre, Singapore, Republic of Singapore.

E-mail address: kennypang@hotmail.com.

AQ:2

suspension technique (Repose; InluENT Medical LLC, Concord, NH) achieves tongue base stabilization. Using a U-shaped drill inserter that drills “backwards,” a self-tapping bone anchor is inserted through the oral cavity into the inner table of the mandible. The integrated suture material is passed through the tongue in the midline, resulting in tongue base support.

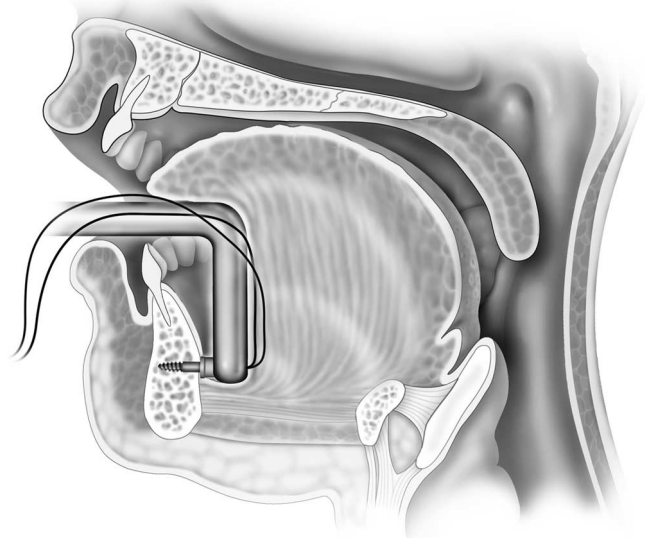
## The Repose Bone Screw system

### Description of device

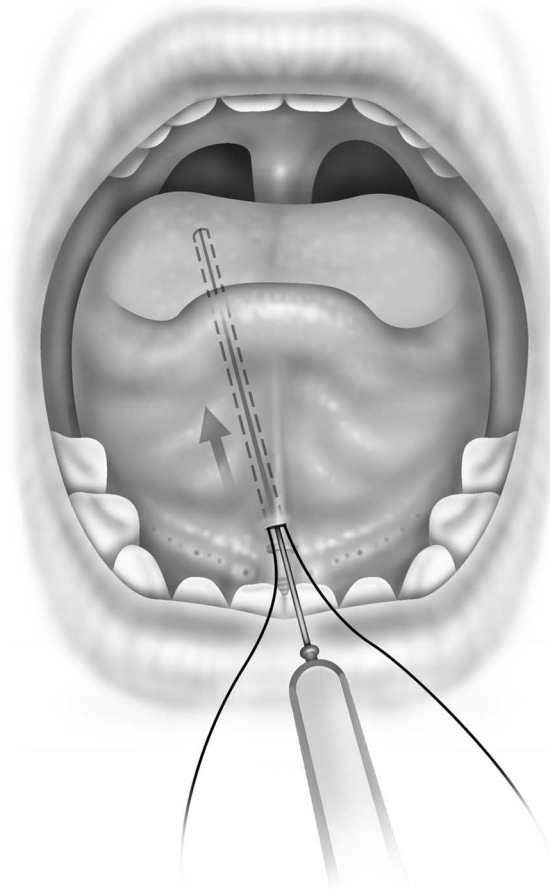
The Repose Bone Screw system is intended for suspension of the tongue base with a number 1 Prolene suture (Ethicon Endo-Surgery, Inc, Cincinnati, OH) attached to a bone screw. The system comes with a battery operated bone screw inserter used to drive the screw into the inner table of the mandible through the floor of mouth. The bone screw is a sharp-tipped small diameter titanium screw with 2 polypropylene monofilament number 1 sutures crimped into its base and is self-tapping.

### Surgical procedure

The procedure is performed with the patient under general anesthesia and in the supine position. The authors perform the procedure with orotracheal intubation, and a bite block within the oral cavity keeping the mouth open and isolating the endotracheal tube to one side. Local anesthetic with a vasoconstrictor is injected into the floor of the mouth at the frenulum. A 1.5-cm incision is made in the midline of the frenulum, between the Wharton ducts, taking care not to injure the ductal orifices. A curved hemostat is introduced into the floor of the mouth through the incision, and the periosteum of the inner table of the mandible is then lifted off with this clamp. The screw inserter is placed so that the screw is placed through the floor of the mouth in the



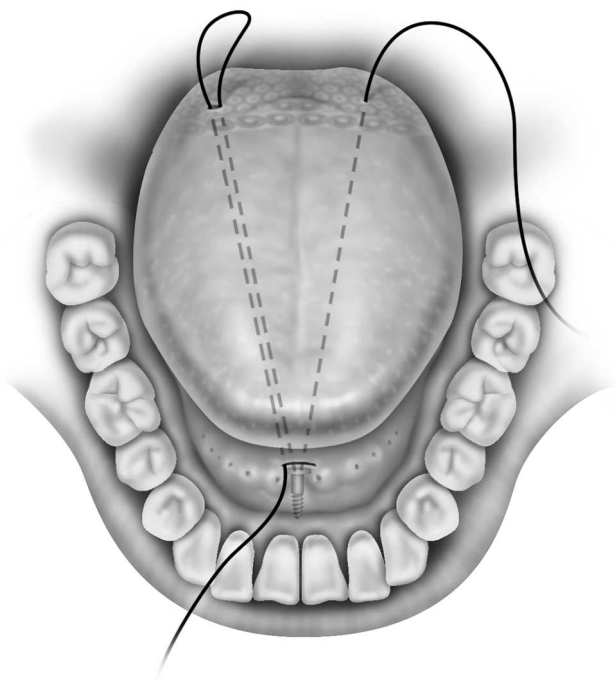
**Figure 1** The drill inserting the screw into the inner table of the mandible.



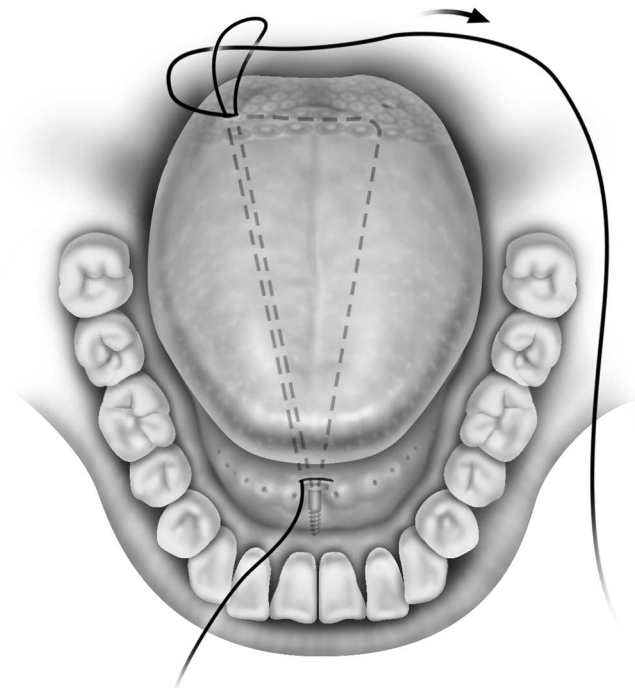
**Figure 2** The suture passer passing the suture loop from the frenulum incision to the base of tongue.

midline, posterior to the Wharton duct. Once inserted, the screw is pressed against the mandible, below the tooth roots and at the symphysis menti (Figure 1). The inserter is activated until the screw completely penetrates the mandible and then the inserter is carefully removed. After the screw is completely embedded in the inner table of the mandible, the 2 sutures now protrude through the incision. A suture passer is used to pass an empty suture loop through the incision in the floor of the mouth to an exit point at the tongue base at the circumvallate papillae, about 1.5-cm lateral to the midline on the right side (for a right-handed surgeon) (Figure 2). The number 1 Prolene suture is then passed, with the same suture passer, through the incision to another exit point at the opposite side of the tongue base, also about 1.5-cm lateral to the midline (Figure 3). Care is taken not to pass the needle too laterally to avoid injury to the neurovascular bundle. This number 1 Prolene suture is then threaded onto an empty Mayo needle. This Mayo needle is passed back into the exit point of the suture and then passed submucosally past the midline to the exit point of the previously placed suture loop (Figure 4). The Prolene suture is now threaded onto the empty suture loop and pulled back to the anterior intraoral space, thereby creating a triangular-shaped suture pass, the base of which is in the posterior tongue (Figures 5 and 6). The 2 suture ends are now tied and secured into the floor of the mouth and buried deeply. A small dimple should be felt at the base of the tongue during this tying process (Figure 7). The mucosal

69  
70  
71  
72  
73  
74  
75  
76  
77  
78  
79  
80  
81  
82  
83  
84  
85  
86  
87  
88  
89  
90  
91  
92  
93  
94  
95  
96  
97  
98  
99  
100  
101  
102  
103  
104  
105  
106  
107  
108  
109  
110  
111  
112  
113  
114  
115  
116  
117  
118  
119  
120  
121  
122  
123  
124  
125  
126  
127  
128



**Figure 3** The suture loop on the right side of the tongue, and the Prolene suture already passed through to the left side of the tongue base.



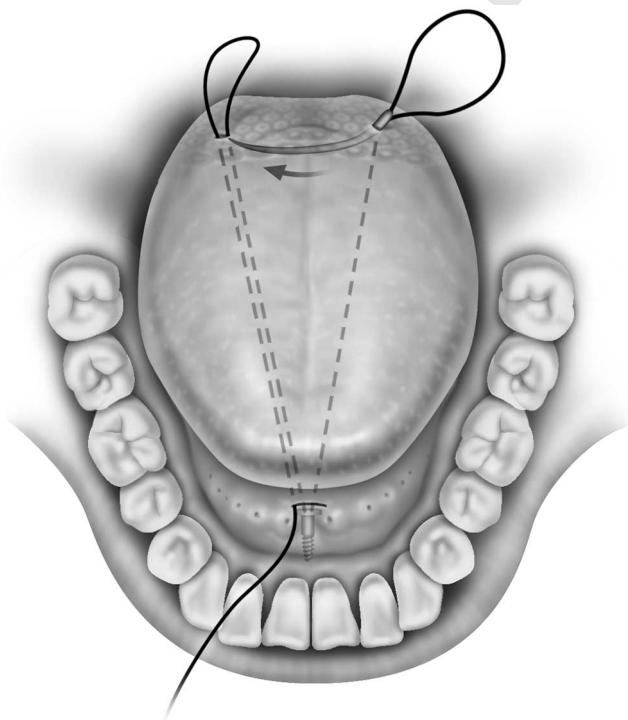
**Figure 5** The Prolene suture threaded through the suture loop and being pulled to the front.

incision is sutured with an absorbable material avoiding the Wharton duct.

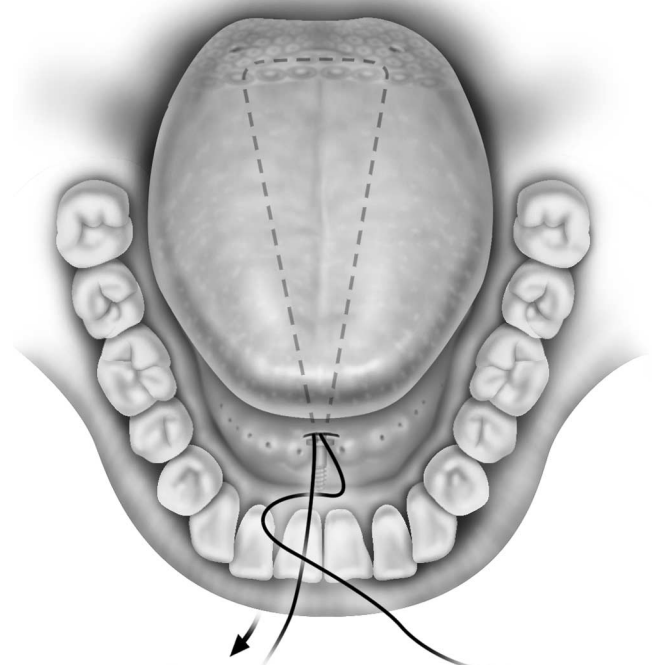
**Discussion**

Surgical treatment of obstructive sleep in patients with multilevel obstruction (Fujita II)<sup>14</sup> should include both palatal

surgery and surgery aimed at increasing the retrolingual space. Most surgical tongue base procedures are either difficult to perform or cause substantial patient morbidity. The minimally invasive tongue suspension procedure to prevent tongue base collapse has been shown to have few complications and minimal morbidity for the patient. This technique is aimed at stabilizing the tongue base by creating a sling for the tongue base and adding rigidity by virtue of the scar tissue, which ultimately encases the suture anchored

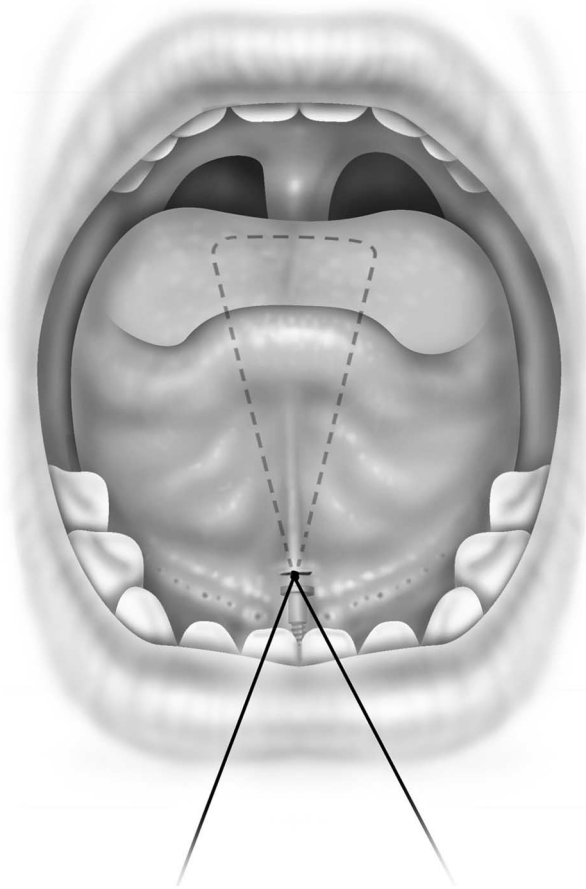


**Figure 4** The free curved needle passing through the tongue base from the left to right side, passing the Prolene suture with it.



**Figure 6** The triangular-shaped Prolene suture submucosally throughout its course.

69  
70  
71  
72  
73  
74  
75  
76  
77  
78  
79  
80  
81  
82  
83  
84  
85  
86  
87  
88  
89  
90  
91  
92  
93  
94  
95  
96  
97  
98  
99  
100  
101  
102  
103  
104  
105  
106  
107  
108  
109  
110  
111  
112  
113  
114  
115  
116  
117  
118  
119  
120  
121  
122  
123  
124  
125  
126  
127  
128



**Figure 7** The suture tied in place.

anteriorly. This procedure is usually performed together with a uvulopalatopharyngoplasty as part of multilevel surgery. There are numerous studies showing the efficacy of the tongue base stabilization technique, some with very promising results.

Fibbi et al<sup>15</sup> showed a significant reduction in the apnea-hypopnea index (AHI) and daytime sleepiness in 10 patients who underwent this procedure for severe OSA. Woodson<sup>16</sup> showed a mean decrease in the AHI from  $35.4 \pm 13.7$  to  $24.5 \pm 14.5$  ( $P < 0.001$ ) in 28 patients with OSA. There was also significant improvement in daytime sleepiness scores and reduction in snoring. Using the criteria of a reduction of the AHI by 50% and postoperative AHI  $< 20$ , Terris et al<sup>17</sup> reported a success rate of 67% after a 6-month postoperative follow-up in patients who had undergone a concomitant palatopharyngoplasty. The same investigators published results from a prospective randomized trial comparing the tongue suspension with genioglossus advancement, and there was a slight advantage of the tongue suspension over tongue advancement.<sup>18</sup> Sorrenti et al<sup>19</sup> also found a similar success rate with this tongue suspension suture at 62% of 15 patients with OSA after 6 months of follow-up. A Turkish group<sup>20</sup> reported the most promising success rate of 81.8% in 22 patients with severe OSA. They had a mean AHI reduction from  $47.5 \pm 15.7$  to  $17.3 \pm 14.1$  after a 12-month follow-up. Snoring and daytime sleepiness had reduced significantly as well. However, other investigators have described less impressive success rates, ranging from 51% to 55% at 12 months of follow-up.<sup>21,22</sup>

Complications include pain, swallowing, and speech problems that are usually mild and self limited. No long-term speech or swallowing problems have been reported. In some patients, there was mild local infection and irritation of the floor of mouth surrounding the suture knot, and there have been rare reports of submandibular adenitis. Carefully burying the knot deep in the muscle tissue and administering perioperative antibiotics can prevent this complication.

## Conclusions

The minimally invasive tongue suspension procedure has been shown to be an important part of the sleep surgery armamentarium, especially in patients with predominantly tongue base collapse. The procedure is simple, complications are minimal, and the results are promising.

## References

1. Young T, Palta M, Dempsey J, et al: The occurrence of sleep-disordered breathing among middle-aged adults. *N Engl J Med* 328:1230-1235, 1993
2. Young T, Evans L, Finn L, et al: Estimation of the clinically diagnosed proportion of sleep apnea syndrome in middle aged men and women. *Sleep* 20:705-706, 1997
3. Nieto JF, Young TB, Lind BK, et al: Association of sleep-disordered breathing, sleep apnea, and hypertension in a large community-based study. *Sleep Heart Health Study. JAMA* 283:1829-1836, 2000
4. Peppard PE, Young T, Palta M, et al: Prospective study of the association between sleep-disordered breathing and hypertension. *N Engl J Med* 342:1378-1384, 2000
5. Robinsky G, Miller M, Anlt K, et al: Spontaneous platelet activation and aggregation during obstructive sleep apnea and its response to therapy with nasal continuous positive airway pressure. A preliminary investigation. *Chest* 108:625-630, 1995
6. Ranqemark C, Hedner JA, Carlson JT, et al: Platelet function and fibrolytic activity in hypertensive and normotensive sleep apnea patients. *Sleep* 18:188-194, 1995
7. Dean RT, Wilcox I: Possible atherogenic effects of hypoxia during obstructive sleep apnea. *Sleep* 16:S15-S22, 1996
8. Schulz R, Mahmoudi S, Hattar K, et al: Enhanced release of superoxide from polymorphonuclear neutrophils in obstructive sleep apnea. *Am J Respir Crit Care Med* 162:566-570, 2000
9. Mooe T, Franklin KA, Holmstrom K, et al: Sleep disordered breathing and coronary artery disease: Long term prognosis. *Am J Resp Crit Care Med* 164:1910-1913, 2001
10. Peker Y, Hedner J, Kraiczi H, et al: Respiratory disturbance index: An independent predictor of mortality in coronary artery disease. *Am J Resp Crit. Care Med* 162:81-86, 2000
11. Bradley TD: Right and left ventricular functional impairment and sleep apnea. *Clin Chest Med* 13:459-479, 1992
12. Kuhlo W, Doll E, Frank MD: Successful management of Pickwickian syndrome using long-term tracheostomy [in German]. *Dtsch Med Wochenschr* 94:1286-1290, 1969
13. Conway WA, Victor LD, Magilligan J: Adverse effects of tracheostomy for sleep apnoea. *JAMA* 264:347-350, 1981
14. Fujita S, Conway W, Zorick F: Surgical correction of anatomic abnormalities of obstructive sleep apneas: Uvulopalatopharyngoplasty. *Otolaryngol Head Neck Surg* 89:923-934, 1981
15. Fibbi A, Presta A, Fasciolo G: A new mini-invasive technique for the treatment of sleep breathing disorders: Preliminary results of a clinical experience [in Italian]. *Acta Otorhinlaryngol Ital* 19:21-25, 1999
16. Woodson BT: A tongue suspension suture for obstructive sleep apnea and snorers. *Otolaryngol Head Neck Surg* 124:297-303, 2001

17. Terris DJ, Kunda LD, Gonella MC: Minimally invasive tongue base surgery for obstructive sleep apnoea. *J Laryngol Otol* 116:716-721, 2002

18. Thomas AJ, Chavoya M, Terris DJ: Preliminary findings from a prospective, randomized trial of two tongue base surgeries for sleep disordered breathing. *Otolaryngol Head Neck Surg* 129:539-546, 2003

19. Sorrenti G, Piccin O, Latini G, et al: Tongue base suspension technique in obstructive sleep apnea: Personal experience [in Italian]. *Acta Otorhinolaryngol Ital* 23:274-280, 2003

20. Omur M, Ozturan D, Elez F, et al: Tongue base suspension combined with UPPP in severe OSA patients. *Otolaryngol Head Neck Surg* 133:218-223, 2005

21. Kuhnle TS, Schurr C, Wagner B, et al: Morphological changes of the posterior airway space after tongue base suspension. *Laryngoscope* 115:475-480, 2005

22. DeRowe A, Gunther E, Fibbi A, et al: Tongue base suspension with soft tissue to bone anchor for obstructive sleep apnea: Preliminary clinical results of a new minimally invasive technique. *Otolaryngol Head Neck Surg* 123:667-668, 2000

UNCORRECTED PROOF

69  
70  
71  
72  
73  
74  
75  
76  
77  
78  
79  
80  
81  
82  
83  
84  
85  
86  
87  
88  
89  
90  
91  
92  
93  
94  
95  
96  
97  
98  
99  
100  
101  
102  
103  
104  
105  
106  
107  
108  
109  
110  
111  
112  
113  
114  
115  
116  
117  
118  
119  
120  
121  
122  
123  
124  
125  
126  
127  
128

## AUTHOR QUERIES

### AUTHOR PLEASE ANSWER ALL QUERIES

1

AQ1— Please provide keywords.

AQ2— Is the manufacturer information correct in the sentence beginning “The minimally invasive tongue suspension technique...”?

---