

Nasal septal abscess: an unusual complication of acute sphenoid-ethmoiditis

KENNY PETER PANG, DHARAMBIR S. SETHI

Abstract

Nasal septal abscess complicating acute sinusitis is rare. There have been very few reports in the literature of this condition. We present a 12-year-old male with a nasal septal abscess complicating acute pansinusitis.

Key words: Nasal Septum; Abscess; Sinusitis/complications

Introduction

Orbital and intracranial complications resulting from acute sinusitis are well documented.¹ On the other hand, a nasal septal abscess complicating acute sinusitis is rare. A nasal septal abscess (NSA) results from the collection of purulent material between the cartilage or bony septum and its normally applied mucoperichondrium or mucoperiosteum.^{2,3} Nasal septum abscesses are fairly uncommon, most of the reported cases are secondary to a nasal septal haematoma sustained from trauma. Atraumatic nasal septal abscesses due to ethmoiditis or sphenoiditis are even rarer. Beck in 1945 documented two cases of nasal septal abscess secondary to acute ethmoiditis.⁴ Collins in 1985 described a case of nasal septal abscess from acute sphenoiditis.⁵ Matsuba in 1986 reported a patient with a nasal septal abscess secondary to acute ethmoid and sphenoid sinusitis associated with sphenoid sinus mucophyloceles.⁶ Using the Medline and Google.com search applications, these are the only four reported cases of nasal septal abscess complicating acute sinusitis, for the past 55 years. We report another case of a nasal septal abscess secondary to acute sphenoid-ethmoiditis.

Case report

A 12-year-old boy presented to the Emergency department with right peri-orbital oedema extending over the right cheek for three days. He also complained of bilateral nasal obstruction of five days duration. The child had initially consulted a family physician for bilateral yellowish nasal discharge, headaches and facial congestion. The family physician treated him with antihistamines and oral antibiotics.

Physical examination revealed the child to be febrile at 38° Celsius, mild right cheek and right peri-orbital swelling was noted. Anterior rhinoscopy showed bilateral dull purple swelling of the nasal septum, bulging into the nasal cavity. Oedema of the nasal mucosa and mucopus were noted in the nasal cavity bilaterally. The post-nasal space, oral cavity and neck examination were unremarkable. A complete blood count showed a raised total white count of $15.4 \times 10^9/L$ and a raised white cell differential count of 81.5 per cent neutrophils. In view of the clinical symptoms

of sinusitis associated with right peri-orbital oedema, the clinical impression was that of acute sinusitis complicated by a nasal septal abscess. The patient was started on intravenous amoxicillin clavulanate 1.2 g eight-hourly and topical nasal decongestants.

A plain axial and post-contrast coronal computed tomography (CT) of the paranasal sinuses revealed a nasal septal abscess completely filling the entire nasal cavity bilaterally. Both osteomeatal units and sphenoid-ethmoidal recesses were obstructed. Pansinusitis was also evident. There was also right cheek and right eyelid oedema evident. The globes and retro-orbital area were normal. Cavernous sinuses were normal (Figures 1, 2 and 3). The CT scan confirmed the diagnosis of acute sinusitis complicated by a nasal septal abscess.

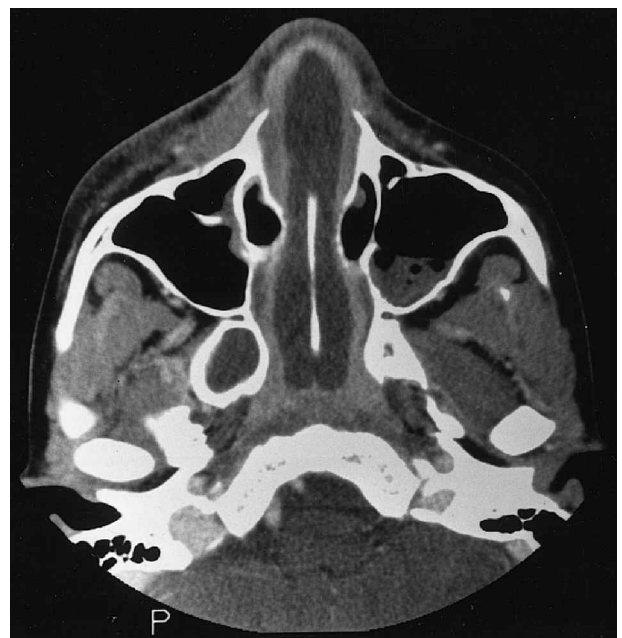


FIG. 1

Axial CT scan of the paranasal sinuses showing a nasal septal abscess.

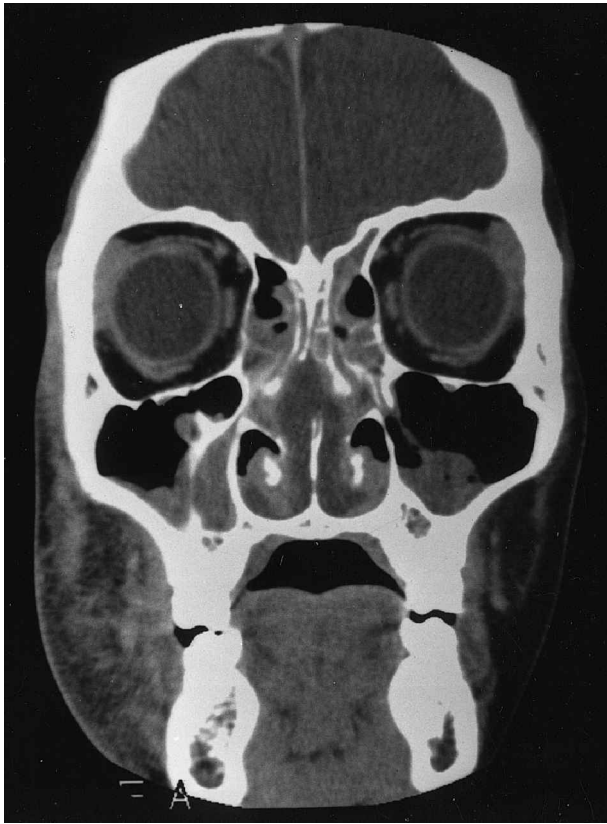

FIG. 2

Coronal CT scan of the paranasal sinuses showing a nasal septal abscess and pansinusitis.

After local infiltration of two per cent lignocaine and 1:80 000 adrenalin into the left nasal septal mucosa, a Killian's incision was made and the nasal septal abscess

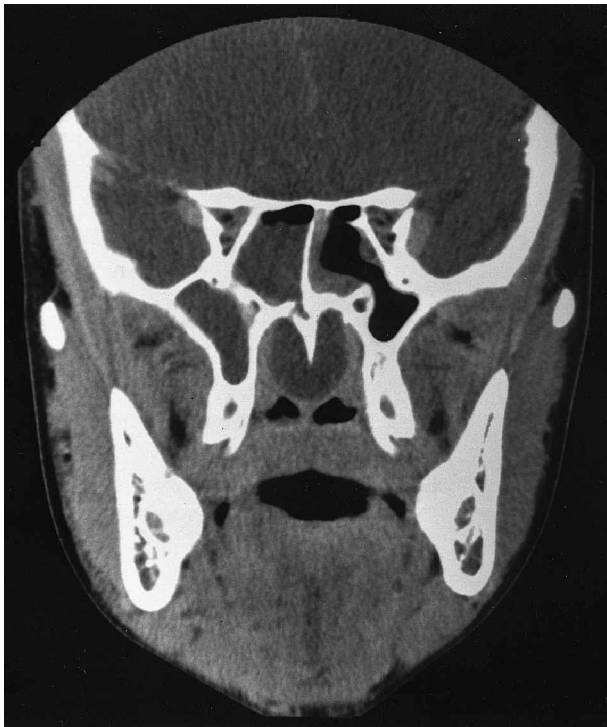

FIG. 3

Coronal CT scan of the paranasal sinuses revealing right sphenoiditis, the right sphenoid ostia and a nasal septal abscess.

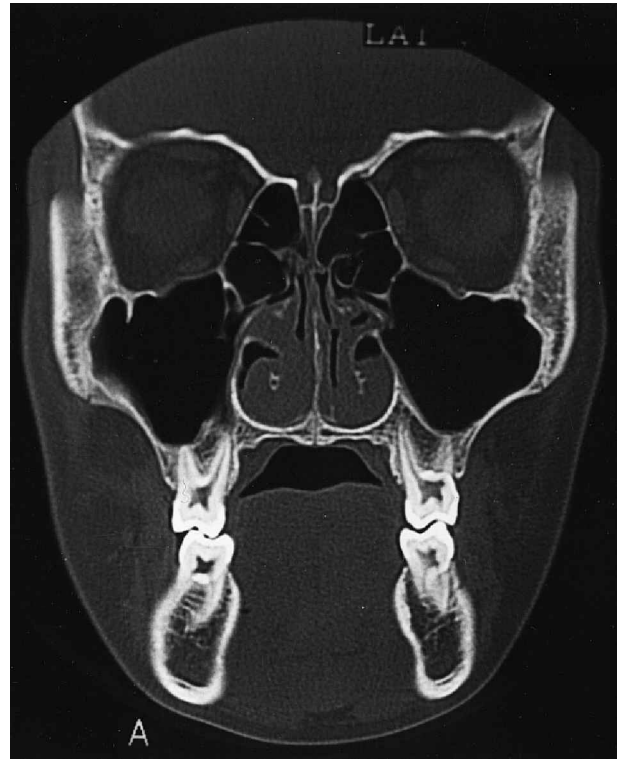

FIG. 4

Post-treatment coronal CT scan of the paranasal sinuses showing resolved sinusitis.

was drained. Purulent discharge was immediately obtained and suctioning of the abscess cavity was performed. An aspirate from the abscess was sent for culture, but this did not grow any pathogens. A soft Penrose drain was inserted into the abscess cavity, and secured with silk stay sutures. Bilateral Merocel nasal packing was inserted. This were removed after 24 hours. The Penrose drain was kept in situ for three days. The patient was discharged home after his

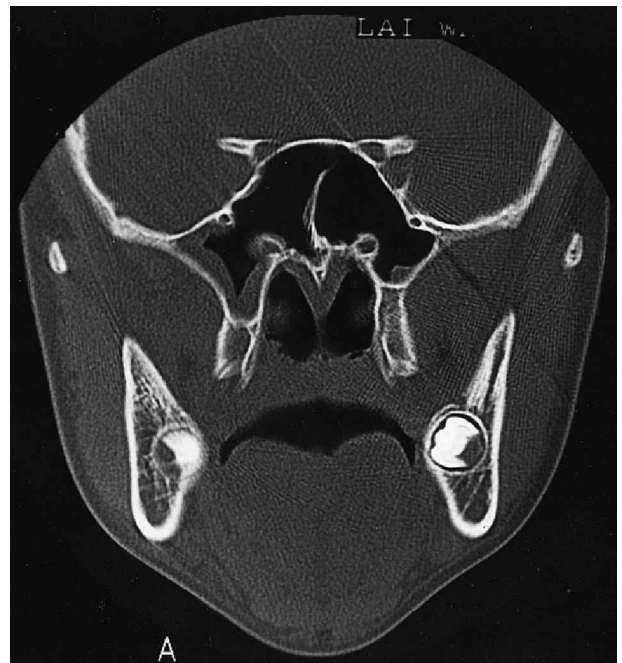


FIG. 5

Post-treatment coronal CT scan of the paranasal sinuses revealing residual thickening of the right sphenoid sinus mucosa.

fever had subsided, on oral amoxicillin clavulanate for a further 10 days. The patient was seen at our out-patient clinic after two months, the patient was well. Nasoendoscopy revealed complete resolution of the sinusitis. The nasal septum looked normal. The osteomeatal complex and sphenoid-ethmoidal recesses were normal bilaterally. Post-treatment CT scans of the paranasal sinuses also showed resolution of the nasal septal abscess and sinusitis (Figures 4 and 5).

Discussion

Orbital and intra-cranial complications of sinusitis are well documented. Orbital involvement is the most common complication of acute sinusitis, as the orbital contents are separated from the ethmoid labyrinth by only the thin lamina papyracea. This orbital involvement includes pre-septal cellulitis, orbital cellulitis, subperiosteal abscess, intra-orbital abscess and optic nerve compression.⁷ Intra-cranial complications such as extradural abscess, meningitis, subdural abscess, intracerebral abscess and cavernous sinus thrombosis are rare but may be fatal. Another rare complication of acute sinusitis is a nasal septal abscess, as described in our patient.

Nasal septal abscess is defined as a collection of purulent material between the cartilage or bony septum and its normally applied mucoperichondrium or mucoperiosteum.^{2,3} The most common presentation of nasal septal abscess is bilateral nasal obstruction. Other symptoms include nasal pain, malaise, fever, headache, and tenderness of the nose. Most patients have a history of trauma. Spontaneous nasal septal abscesses are rare, acute ethmoiditis, acute sphenoiditis and dental infections⁸ have been documented as causes.

The pathophysiology of a nasal septal abscess depends on its aetiology. Collins believed that isolated acute sphenoiditis can cause the formation of a nasal septal abscess via the direct subperiosteal extension of the anterior surface of the sphenoid bone, stripping the periosteum of the vomer and perpendicular plate of ethmoids to the subperichondrial surface of the quadrilateral cartilage.⁵ We believe that this may have been the mechanism by which the abscess was formed in this patient. Other possible mechanisms include direct spread through the bony fissures, congenital bony deformities, or through thrombophlebitis.

The commonest organism cultured from nasal septal abscess is *Staphylococcus aureus*. *Streptococcus pneumoniae*, *Streptococcus milleri*, *Streptococcus viridans*, *Staphylococcus epidermidis*, *Haemophilus influenzae*, and anaerobic organisms have also been cultured.^{2,8} In our patient, the culture did not grow any organism as the child had been treated with antibiotics by the family physician.

The management of these cases consists of incision and drainage of the abscess. The aspirate is sent for culture and sensitivity, and intravenous antibiotics instituted. A soft

drain (Penrose) is inserted into the abscess cavity and bilateral nasal packing is recommended to prevent re-accumulation. The nasal packs are removed after 24 to 48 hours and nasal toilet performed. Systemic antibiotics, based on culture and sensitivity results, are continued for about two weeks.

Delayed management of a nasal septum haematoma can result in compromise of the vascular supply to the septal cartilage resulting in ischaemic necrosis of the cartilage and saddle nose deformity. Other complications of nasal septal abscess documented include sepsis, bacteraemia, meningitis, and maxillary hypoplasia. Hence, in order to avoid these unnecessary complications, diagnosis should be accurate and treatment prompt.

Acknowledgement

We would like to thank Lee Shu Ying, medical student, for helping with the literature research.

References

- 1 Chandler JR, Langenbrunner DJ, Stevens ER. The pathogenesis of orbital complication in acute sinusitis. *Laryngoscope* 1970;**80**:1414–28
- 2 Canty PA, Berkowitz RG. Hematoma and abscess of the nasal septum in children. *Arch Otolaryngol* 1996;**122**:1373–6
- 3 Ambrus PS, Eavey RD, Baker AS, Wilson WR, Kelly JH. Management of nasal septal abscess. *Laryngoscope* 1981;**91**:572–82
- 4 Beck A. Abscess of the nasal septum complicating acute ethmoiditis. *Arch Otolaryngol* 1945;**42**:275–9
- 5 Collins MP. Abscess of the nasal septum complicating acute sphenoiditis. *J Laryngol Otol* 1985;**99**:715–9
- 6 Matsuba H, Thawley S. Nasal septal abscess: unusual causes, complications, treatment, and sequelae. *Ann Plast Surg* 1986;**16**:161–6
- 7 Schramm VL, Myers EN, Kennerdell JS. Orbital complications of acute sinusitis: evaluation, management and outcome. *Trans Am Acad Ophthalmol Otolaryngol* 1978;**86**:221
- 8 da Silva M, Helman J, Eliachar I, Joachims HZ. Nasal septal abscess of dental origin. *Arch Otolaryngol* 1982;**108**:380–1

Address for correspondence:

Dr Kenny Peter Pang,
Department of Otolaryngology,
Singapore General Hospital,
Outram Road,
Singapore 169608

Fax: 0065 2262079

Dr K. Pang takes responsibility for the integrity of the content of the paper.

Competing interests: None declared
