

RUSH: Operative Techniques in Otolaryngology article for proofing (# 0217)

=====

Dear Author,

The proof of your article, to be published by Elsevier in Operative Techniques in Otolaryngology, is available as a "PDF" file at the following URL:

<http://rapidproof.cadmus.com/RapidProof/retrieval/index.jsp>

Login: your e-mail address

Password: ----

The site contains 1 file. You will need to have Adobe Acrobat Reader software to read these files. This is free software and is available for user download at: <http://www.adobe.com/products/acrobat/readstep.html>

After accessing the PDF file, please:

- 1) Carefully proofread the entire article, including any tables, equations, figure legends and references.
- 2) Ensure that your affiliations and address are correct and complete.
- 3) Check that any Greek letter, especially "mu", has translated correctly;
- 4) Verify all scientific notations, drug dosages, and names and locations of manufacturers;
- 5) Be sure permission has been procured for any reprinted material.
- 6) Answer all author queries completely. They are listed on the last page of the proof;

You may choose to list the corrections (including the replies to any queries) in an e-mail and return to me using the "reply" button. Using this option, please refer to the line numbers on the proof. If, for any reason, this is not possible, mark the corrections and any other comments (including replies to questions) on a printout of the PDF file and fax this to Nick DeAngelis (fax #: 717 738 9360), or mail to the address given below.

If you submitted usable colour figures with your article they will appear in colour on the web, at no extra charge, as you can see in the attached PDF proof of your article. In the printed issue, colour reproduction depends on journal policy and whether or not you agree to bear any costs.

Do not attempt to edit the PDF file (including adding post-it type notes).

Within 48 hours, please return the following to the address given below:

- 1) Corrected PDF set of page proofs
- 2) Print quality hard copy figures for corrections if necessary (we CANNOT accept figures on disk at this stage). If your article contains color illustrations and you would like to receive proofs of these illustrations, please contact us within 48 hours.

If you have any problems or questions, please contact me. **PLEASE ALWAYS INCLUDE YOUR ARTICLE NUMBER (0217) WITH ALL CORRESPONDENCE.**

Sincerely,

Nick DeAngelis

Issue Manager, YOTOT

Cadmus

300 West Chestnut Street

Ephrata, PA 17522

Ph: 717 721-2603, Fx: 717 738 9360

E-mail: [deangelisn@cadmus.com](mailto:deangelisn@cadmus.com)



# Lateral pharyngoplasty in the treatment of obstructive sleep apnea

Kenny P. Pang, FRCSEd, FRCSI(OTO), FAMS(ORL)

From the Sleep Surgery Service, Department of Otorhinolaryngology, Tan Tock Seng Hospital, Singapore.

## KEYWORDS



The lateral pharyngeal wall has been well documented to be the cause of collapse in many patients with obstructive sleep apnea (OSA). The inability to correct this disorder is a cause of uvulopalatopharyngoplasty failure using traditional techniques. Cahali describes a technique termed lateral pharyngoplasty as a procedure to address the lateral pharyngeal wall collapse in patients with OSA. The technique consists of microdissection of the superior pharyngeal constrictor muscle within the tonsillar fossa, sectioning of this muscle, and suturing of the created laterally based flap of that muscle to the same-side palatoglossus muscle. The preliminary results are promising and side effects minimal. This procedure can be performed alone or as part of the multilevel surgical algorithm in the treatment of OSA.  
© 2006 Elsevier Inc. All rights reserved.

The vibration of the structures in the oral cavity (ie, the soft palate, uvula, tonsils, base of tongue, epiglottis, and lateral pharyngeal walls) causes snoring. These tissues that vibrate have been believed to collapse and cause airway obstruction under negative pressure in obstructive sleep apnea (OSA). It is well documented that apnea and hypopnea occur when inspiratory transpharyngeal pressure exceeds the pharyngeal dilating muscle action.<sup>1</sup> Most investigators concur that the pathophysiology of OSA lies within the balance of the box and the contents' theory. The box being the facial skeletal framework, and the contents would refer to the soft tissues within the upper airway. Patients with adenotonsillar hypertrophy or obese patients with thick fatty redundant lateral pharyngeal walls have a crowded upper airway, with very little space for airflow. Patients with retrognathia have a posteriorly displaced tongue, therefore increasing the likelihood of airway compromise during sleep.

Lateral pharyngeal muscle wall collapse has been important in the pathogenesis of OSA in imaging studies.<sup>2,3</sup> It has also been noted to be an important level of collapse during the Muller maneuver.<sup>4</sup> Terris et al<sup>4</sup> have documented that

the lateral pharyngeal wall has significant collapse in many patients with OSA.

Surgical procedures for the treatment of OSA have traditionally been to reduce the soft tissue bulk, in the form of a uvulopalatopharyngoplasty (UPPP), palatal advancement, or tongue base reduction; skeletal jaw surgery has also showed success in the form of maxillomandibular advancement. To my knowledge, there has been no specific, effective procedure that can address this lateral pharyngeal wall collapse in patients with OSA.

First described by Cahali,<sup>5</sup> the lateral pharyngoplasty was aimed at addressing the lateral pharyngeal wall collapse in patients with OSA. The procedure showed promising results, with minimal side effects and complications.

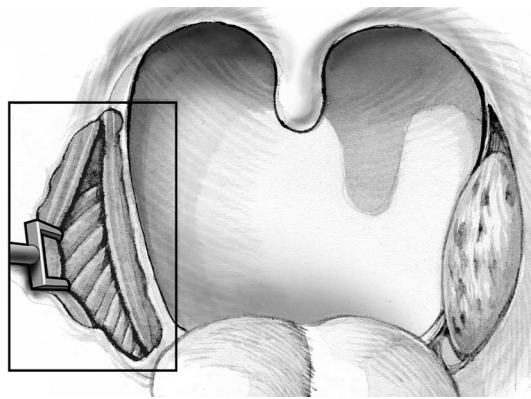
## The lateral pharyngoplasty

### Surgical procedure

The procedure is performed with the patient under general anesthesia and in the supine position. The authors perform the procedure with orotracheal intubation, and a Boyle-Davis mouth gag within the oral cavity keeping the mouth open and isolating the endotracheal tube forwards. Cahali<sup>5</sup> describes a procedure using the operative microscope fitted with a 300-mm object lens, with 10× and 16× magnifications. The surgery has 3 parts: tonsillectomy,

**Address reprint requests and correspondence:** Kenny Peter Pang, FRCSEd, FRCSI(OTO), FAMS(ORL), Department of Otolaryngology, Tan Tock Seng Hospital, 11 Jalan Tan Tock Seng, Singapore, Republic of Singapore.

E-mail address: kennypang@hotmail.com.



**Figure 1** Isolation of the palatopharyngeus muscle and retracting laterally, and identifying (inset) the horizontal fibers of the constrictors.

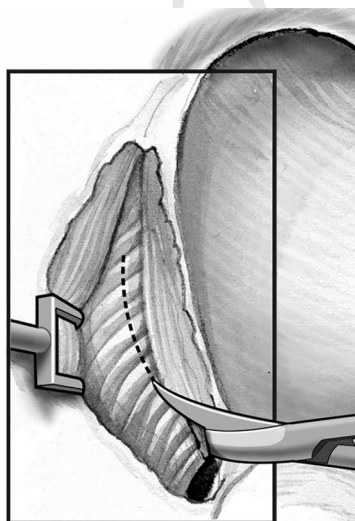
AQ: 5

tightening of the superior constrictor muscle, and closure with a laterally based palatal flap.

**F1** A bilateral tonsillectomy is performed (Figure 1). An incision is extended superiorly from the tonsil fossa, and the superior pharyngeal constrictor muscle is identified and isolated from the palatopharyngeus muscle. The superior pharyngeal constrictor muscle is elevated within the tonsillar fossa as far as the glossopharyngeal part (Figure 2).  
**F2** Parallel to the palatopharyngeus muscle, the superior pharyngeal constrictor muscle is sectioned from cranial to caudal direction, resulting in 2 muscle flaps, 1 medially based and 1 laterally based. The medially based flap is not further manipulated, while the laterally based flap is sutured anteriorly to the same-side palatoglossus muscle with 3 separate sutures (Figure 3). A half-thickness incision is made on the anterior surface of the soft palate, beginning at the base of the uvula and connecting to the previous superior extension from the tonsil fossa.<sup>5</sup> Ventral soft palate mucosa, palatoglossus muscle, and periuvular fat are atraumatically removed, preserving dorsal palatal mucosa (Figure 4). The dorsal palatal mucosa is then incised close to the uvula, creating a laterally based mucosal and myomucosal flap. The superior and palatine flaps are sutured in a Z-plasty

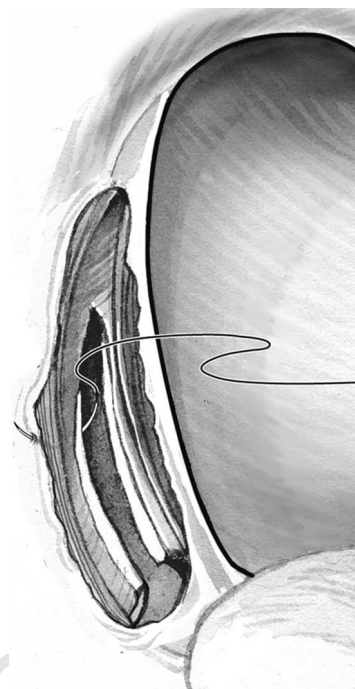
F3

F4



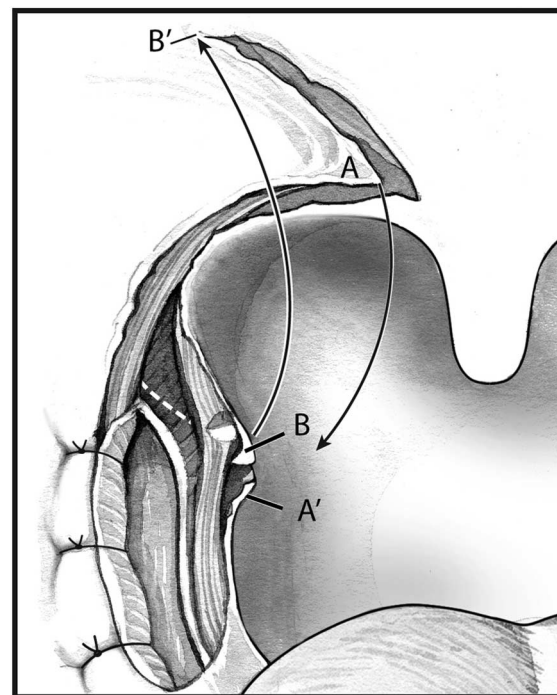
**Figure 2** Isolation of the superior constrictor and dividing (inset) it vertically.

AQ: 6



**Figure 3** Suturing of the lateral fibers of the constrictors to the lateral palatopharyngeus muscles.

fashion (Figure 5).<sup>5</sup> A transverse subtotal section of the palatopharyngeus muscle may be required to allow the flap to close (Figure 6). Care should be taken to save and preserve as much mucosa as possible. Suturing the inferior palatopharyngeus muscle flap to the anterior pillar closes the inferior part of the tonsillar fossa. The uvula is mini-



**Figure 4** The incision starts from the lateral base of the uvula, extending laterally and superiorly to a point approximately 0.5-cm proximal to the soft palate lateral margin and within a height corresponding to that reached by the lateral superior traction (in a 45° direction) of the upper part of the palatopharyngeus muscle, creating a palatine laterally based flap.

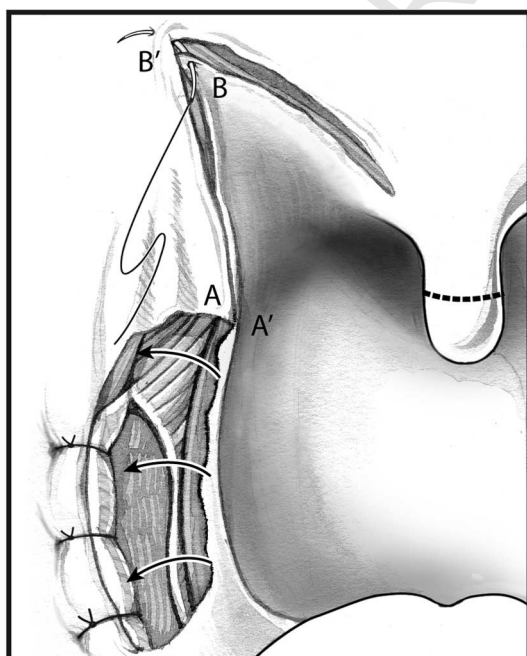
AQ: 7

mally truncated if needed, and the anterior and posterior uvular mucosae are opposed.

### Discussion

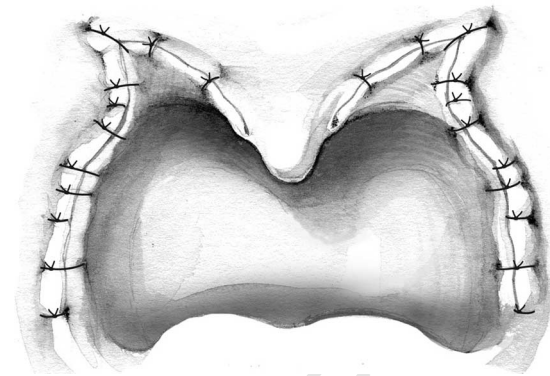
Patients with OSA frequently have multilevel obstruction at the palate, lateral pharyngeal wall, and tongue base. Surgical treatment of these patients with OSA should address all these areas, including the lateral pharyngeal wall collapse. The lateral pharyngeal wall in patients with OSA has been more distensible and collapsible than normal subjects when pressured by airflow.<sup>2</sup> In addition, the lateral pharyngeal walls have also been thicker than normal and are the main contributing anatomic factors in airway narrowing in patients with apnea.<sup>3</sup> Creating tension in the lateral pharyngeal walls may prevent its collapse during sleep in patients with OSA. Repositioning of the jaw with a maxillomandibular advancement pulls the pharyngeal walls anteriorly, stretching the lateral pharyngeal walls, therefore creating this tension. To date, the lateral pharyngoplasty is the only surgical procedure described that deals with the lateral pharyngeal wall collapse.<sup>5</sup> Cahali<sup>5</sup> first described this procedure in 10 patients with moderate-to-severe OSA and who had mainly lateral pharyngeal wall collapse noted on clinical endoscopic examination. All 10 patients had improvement in their apnea-hypopnea index, with a mean of 45.8, reducing to 15.2 ( $P = 0.009$ ) postoperatively, with a mean follow-up of 8 months. There was also improvement in the apnea index, with a reduction from a mean of 22.4 to 4.8 ( $P = 0.005$ ). However, changes in lowest oxygen saturation and rapid eye movement sleep percent were not significant. There were significant swallowing problems in all 10 patients who underwent this procedure. All patients had dysphagia, which ranged from 8 to 70 days postoperatively (mean 20.4). One patient had persistent velopharyngeal in-

AQ: 3



**Figure 5** The superior and palatine flaps are sutured in a Z-plasty fashion.

AQ: 8



**Figure 6** Suturing the inferior palatopharyngeus muscle flap to the anterior pillar then closed the inferior part of the tonsillar fossa.

sufficiency for up to 6 weeks. Another patient had permanent loss of taste to chocolates for 6 months.

Cahali et al<sup>6</sup> compared the lateral pharyngoplasty with the traditional UPPP in 27 patients with OSA. The 15 patients who underwent the lateral pharyngoplasty had a higher reduction in excessive daytime sleepiness, apnea-hypopnea index, and apnea index. There were also improvements in the rapid eye movement sleep percent and morning headaches in patients who had undergone the lateral pharyngoplasty, compared with those who underwent the traditional UPPP. They concluded that patients who underwent the lateral pharyngoplasty technique had better clinical and polysomnographic results.

### Editor's comments

This novel procedure has been shown using evidence-based medicine to be effective in treating patients with OSA who have significant lateral pharyngeal wall collapse. The procedure is composed of several parts. Which part, or parts, contributing to this effect are yet to be determined. Aspects of the procedure are interesting and anatomically sound, yet others are less so. Particular concern is dissection and disruption of the superior constrictor muscle, exposing the parapharyngeal space in which lie major neurovascular structures. Although Cahali<sup>5</sup> noted no major or catastrophic complications, the number of patients treated was small. Patients did have significant dysphagia after the procedure, which eventually resolved. It is the editor's opinion that violating the superior constrictor muscle and exposing the parapharyngeal space to the oral cavity should be avoided. Plicating the lateral pharyngeal wall muscles and performing the lateral pharyngoplasty palatal flap can obtain similar effects.

AQ: 4

### References

1. Remmers JE, De Groot WJ, Sauerland EK, et al: Pathogenesis of upper airway occlusion during sleep. *J Appl Physiol* 44:931-938, 1978
2. Schwab RJ, Gefter WB, Hoffman EA, et al: Dynamic upper airway imaging during awake respiration in normal subjects and patients with sleep disordered breathing. *Am Rev Respir Dis* 148:1385-1400, 1993

3. Schwab RJ, Gupta KB, Gefter WB, et al: Upper airway and soft tissue anatomy in normal subjects and patients with sleep disordered breathing: Significance of the lateral pharyngeal walls. *Am J Respir Crit Care Med* 152:1673-1689, 1995

4. Terris DJ, Hanasono MM, Liu YC: Reliability of the Muller maneuver and its association with sleep disordered breathing. *Laryngoscope* 110: 1819-1823, 2000

5. Cahali MB: Lateral pharyngoplasty: A new treatment for obstructive sleep apnea hypopnea syndrome. *Laryngoscope* 113:1961-1968, 2003

6. Cahali MB, Formigoni GG, Gebrim EM, et al: Lateral pharyngoplasty versus uvulopalatopharyngoplasty: A clinical, polysomnographic and computed tomography measurement comparison. *Sleep* 27:844-846, 2004

UNCORRECTED PROOF

## AUTHOR QUERIES

### AUTHOR PLEASE ANSWER ALL QUERIES

1

AQ5— Is the legend for Figure 1 correct?

AQ6— Is the legend for Figure 2 correct?

AQ7— Please clarify “A” and “B” in the legend for Figure 4.

AQ8— Please clarify “A” and “B” in the legend for Figure 5.

AQ1— Please provide keywords.

AQ2— Is the sentence beginning “A transverse subtotal section of the...” correct?

AQ3— Is “apnea index” correct in the sentence beginning “There was also improvement in the apnea index, with a reduction...”? Please confirm throughout the text.

AQ4— Is the sentence beginning “Particular concern is dissection and disruption...” correct?

---