

RUSH: Otolaryngology-Head and Neck Surgery article for proofing EM # 06872 and PTS # 3891

=====

Dear Author,

The proof of your article, to be published by Elsevier in Otolaryngology-Head and Neck Surgery, is available as a "PDF" file at the following URL:

<http://rapidproof.cadmus.com/RapidProof/retrieval/index.jsp>

Login: your e-mail address

Password: ----

The site contains 1 file. You will need to have Adobe Acrobat Reader software to read this file. This is free software and is available for user download at: <http://www.adobe.com/products/acrobat/readstep.html>

After accessing the PDF file, please:

- 1) Carefully proofread the entire article, including any tables, equations, figure legends, and references.
- 2) Ensure that your affiliations and address are correct and complete.
- 3) Check that any Greek letter, especially "mu," has translated correctly.
- 4) Verify all scientific notations, drug dosages, and names and locations of manufacturers.
- 5) Be sure permission has been procured for any reprinted material.
- 6) Answer all author queries completely. They are listed on the last page of the proof.

You may choose to list the corrections (including the replies to any queries) in an e-mail and return to me using the "reply" button. Using this option, please refer to the line numbers on the proof. If, for any reason, this is not possible, mark the corrections and any other comments (including replies to questions) on a printout of the PDF file and fax this to John Fotia (fax # 212-633-3685), or mail to the address given below.

Do not attempt to edit the PDF file (including adding Post-it type notes).

Within 48 hours, please return the following to the address given below:

- 1) Corrected PDF set of page proofs.
- 2) Print quality hard copy figures for corrections if necessary (we CANNOT accept figures on disk at this stage). If your article contains color illustrations and you would like to receive proofs of these illustrations, please contact us within 48 hours.

If you submitted usable color figures with your article they will appear in color on the web, at no extra charge, as you can see in the attached PDF proof of your article. In the printed issue, color reproduction depends on journal policy and whether or not you agree to bear any costs.

If you have any problems or questions, please contact me. **PLEASE ALWAYS INCLUDE YOUR ARTICLE NUMBER (3891) WITH ALL CORRESPONDENCE.**

Sincerely,
John Fotia
Issue Manager
Elsevier, Inc.
360 Park Avenue South
New York, NY 10010-1710
Phone: 212-633-3870
Fax: 212-633-3685

Email: j.fotia@elsevier.com

ORIGINAL RESEARCH

Expansion sphincter pharyngoplasty: A new technique for the treatment of obstructive sleep apnea

Kenny P. Pang, FRCSEd, FRCSI(OTO), FAMS(ORL), and
B. Tucker Woodson, MD, Singapore, Republic of Singapore, and Milwaukee, WI

OBJECTIVE: In this study, we assessed the efficacy of a new method (expansion sphincter pharyngoplasty [ESP]) to treat obstructive sleep apnea.

STUDY DESIGN: We conducted a prospective, randomized controlled trial.

METHODS: Forty-five adults with small tonsils, body mass index less than 30 kg/m², of Friedman stage II or III, of type I Fujita, and with lateral pharyngeal wall collapse were selected for the study.

RESULTS: The mean body mass index was 28.7 kg/m². The apnea-hypopnea index improved from 44.2 ± 10.2 to 12.0 ± 6.6 ($P < 0.005$) following ESP and from 38.1 ± 6.46 to 19.6 ± 7.9 in the uvulopalatopharyngoplasty group ($P < 0.005$). Lowest oxygen saturation improved from 78.4 ± 8.52% to 85.2 ± 5.1% in the ESP group ($P = 0.003$) and from 75.1 ± 5.9% to 86.6 ± 2.2% in the uvulopalatopharyngoplasty group ($P < 0.005$). Selecting a threshold of a 50% reduction in apnea-hypopnea index and apnea-hypopnea index less than 20, success was 82.6% in ESP compared with 68.1% in uvulopalatopharyngoplasty ($P < 0.05$).

CONCLUSION/SIGNIFICANCE: The ESP may offer benefit in a selected group of OSA patients.

© 2007 American Academy of Otolaryngology–Head and Neck Surgery Foundation, Inc. All rights reserved.

Snororing is produced by the vibration of the soft tissues in the oral cavity—the soft palate, uvula, tonsils, base of tongue, epiglottis, and lateral pharyngeal walls. These vibrating soft tissues, when subjected to negative pressure within the upper airway, may lead to collapse of the upper airway. This collapse (partial or complete) results in upper airway obstruction and apneas. It is known that when the

inspiratory transpharyngeal pressure exceeds the pharyngeal dilating muscle action, these apneas and hypopneas occur.¹ Collapse of the upper airway is usually multilevel, at the level of the velopharynx, the base of tongue, and the lateral pharyngeal walls. Many patients with obstructive sleep apnea (OSA) have bulky thick lateral pharyngeal walls that contribute to the collapse of the upper airway in these patients. The level of collapse is assessed using the Muller maneuver noted with the fiberoptic flexible nasopharyngoscopy. The Muller maneuver is usually graded on a 5-point scale,² from 0 to 4; Terris et al³ described the Muller maneuver finding based on three levels: soft palatal collapse, lateral pharyngeal wall collapse, and base of tongue collapse. Lateral pharyngeal muscle wall collapse has been demonstrated to be important in the pathogenesis of OSA in imaging studies.^{4,5} Hence, lateral pharyngeal wall collapse should be noted and documented, as it plays a significant role in the pathogenesis of OSA. Most authors concur that it is difficult to create, surgically, adequate lateral pharyngeal wall tension to prevent its collapse.

The lateral pharyngoplasty, first described by Cahali,¹ was aimed at addressing the lateral pharyngeal wall collapse in patients with OSA. The procedure showed promising results; however, many patients had dysphagia postoperatively.

The ideal procedure would involve one that is easy to perform, has low morbidity and minimal complications, and does not require any special equipment.

Orticochea⁶ was first to describe the construction of a dynamic muscle sphincter, by isolating the palatopharyn-

From the Pacific Sleep Centre, Singapore, Republic of Singapore (Dr Pang); and Sleep Surgery, Sleep Fellowship Program, Department of Otolaryngology and Communication Sciences, Medical College of Wisconsin, Milwaukee, WI.

Reprint requests: Dr Kenny Peter Pang, Department of Otolaryngology, Pacific Sleep Centre, 20-01 Paragon, Paragon Medical Centre, Singapore, Republic of Singapore.

E-mail address: kennypang@hotmail.com.

geus muscle, and apposing them bilaterally superiorly in the midline, for the treatment of velopharyngeal incompetence in patients with cleft palates. The modified Orticochea procedure was described by Christel et al⁷; the procedure differed by isolating the palatopharyngeus muscle bilaterally, apposing them more superiorly and closing the lateral pharyngeal defects with Z-plasty sutures. Using these procedures, the authors present an innovative technique in creating this tension in the lateral pharyngeal walls, preventing its collapse and reducing the number of apneic episodes. The expansion sphincter pharyngoplasty basically consists of a tonsillectomy, expansion pharyngoplasty, rotation of the palatopharyngeus muscle, a partial uvulectomy, and closure of the anterior and posterior tonsillar pillars. Our hypothesis was that the expansion sphincter pharyngoplasty technique is superior to the traditional uvulopalatopharyngoplasty (UPPP) in patients with small tonsils and significant lateral pharyngeal wall collapse.

MATERIALS AND METHODS

A prospective randomized clinical trial was conducted in 45 consecutive patients. All patient were adults (older than 18 years) who have type I Fujita (retropalatal obstruction) and lateral pharyngeal wall collapse noted on flexible nasoendoscopy. The inclusion criteria included patients with small tonsils (tonsil size 1 and 2), body mass index (BMI) less than 30 kg/m², and Friedman clinical stage II and III who cannot tolerate nasal continuous positive airway pressure (CPAP) therapy or for whom CPAP therapy failed. All patients underwent a thorough clinical examination that included height and weight measurements, neck circumference, BMI, and assessment of the nasal cavity, posterior nasal space, oropharyngeal area, soft palatal redundancy, uvula size and thickness, tonsillar size, and Friedman tongue position. Flexible nasoendoscopy was performed for all patients, and collapse during a Mueller’s maneuver was graded for the soft palate, lateral pharyngeal walls, and base of tongue on a 5-point scale.³ Patients with

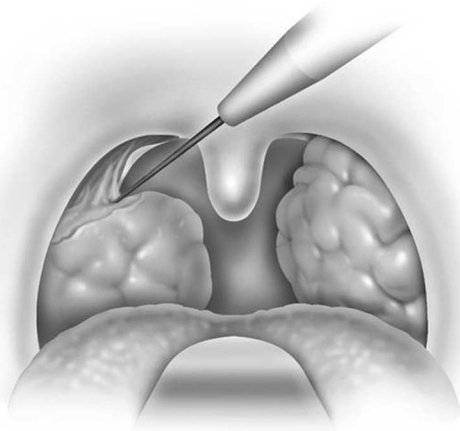


Figure 1 Tonsillectomy is performed.

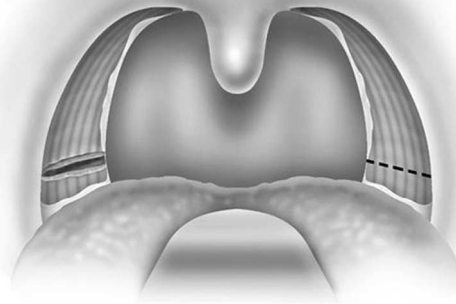


Figure 2 Horizontal incision made to divide the inferior end of the palatopharyngeus muscle.

small tonsils, Friedman clinical stage II or III, type I Fujita, and lateral pharyngeal wall collapse seen on endoscopy were randomized into either the traditional UPPP procedure or the expansion sphincter pharyngoplasty (ESP). All patients had only palatal surgery with no hypopharyngeal surgery. Patients with large tonsils were excluded because we know, from Friedman’s clinical staging of OSA, that patients with large tonsils have a 80% success rate with traditional UPPP; hence, use of this new technique (ESP) on patients with large tonsils will not justify good results if they are obtained. The mean follow-up was 6.5 months. All patients had a postoperative polysomnogram at 6 months. The study was approved by the institutional review board, ethics committee in the institution.

Surgical Technique

The procedure is performed under general anesthesia, with the patient in the supine position. The authors perform the procedure with orotracheal intubation, with a Boyle-Davis mouth gag within the oral cavity to keep the mouth open, and with isolation of the endotracheal tube forward. A bilateral tonsillectomy is performed (Fig. 1). The palatopharyngeus muscle is identified; its inferior end is transected horizontally (Fig. 2) and rotated superolaterally with a figure 8 suture, through the muscle bulk itself, with a Vicryl 3-0 round body needle. The muscle is isolated and left with its posterior surface partially attached to the posterior horizontal superior pharyngeal constrictor muscles (Fig. 3). Sufficient muscle has to be isolated to mobilize the muscle and to allow suturing of the muscle with the Vicryl suture. A superolateral incision is made on the anterior pillar arch bilaterally, identifying the arching fibers of the palatoglossus muscles (Fig. 4). The palatopharyngeus muscle is then attached to the arching fibers of the soft palate anteriorly with a figure 8 suture, through the muscle bulk itself, with a Vicryl 3-0 round body needle (Fig. 5). A partial uvulectomy is then performed. The anterior and posterior tonsillar pillars are then apposed with Vicryl sutures. The same steps are repeated on the opposite side (Fig. 6).

62
63
64
65
66
67
68
69
70
71
72
73
74
75
76
77
78
79
80
81
82
83
84
85
86
87
88
89
90
91
92
93
94
95
96
97
98
99
100
101
102
103
104
105
106
107
108
109
110
111
112
113
114
115

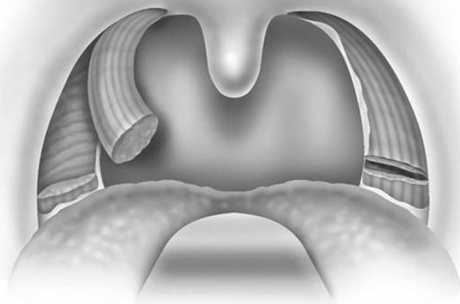


Figure 3 The palatopharyngeus muscle is mobilized, although not completely, with care taken to leave its fascia attachments to the deeper horizontal constrictor muscles.

All patients were monitored in the postanesthesia care unit for 4 hours before being transferred to the high dependency ward for overnight monitoring. Monitoring included continuous pulse oximetry, blood pressure, and pulse rate. They were given adequate analgesia, in the form of anesthetic gargles (Difflam) and lozenges (Difflam), nonsteroidal anti-inflammatory agents (naproxen sodium), and cyclooxygenase 2 inhibitors. Most patients were discharged on the first postoperative day. All patients were encouraged to consume adequate oral fluid hydration and a soft blended diet in the first postoperative week. There were no complications from this procedure, there were no primary or secondary hemorrhages, and there were no fistulas of the soft palate or oral infections.

RESULTS

Forty-five patients were enrolled (22 UPPP, 23 ESP). Forty-one patients were men and 4 were women. The mean age

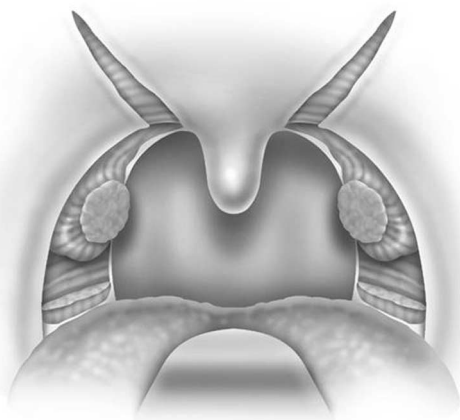


Figure 4 Superolateral incision made on the soft palate, revealing the arching fibers of the palatini muscles.

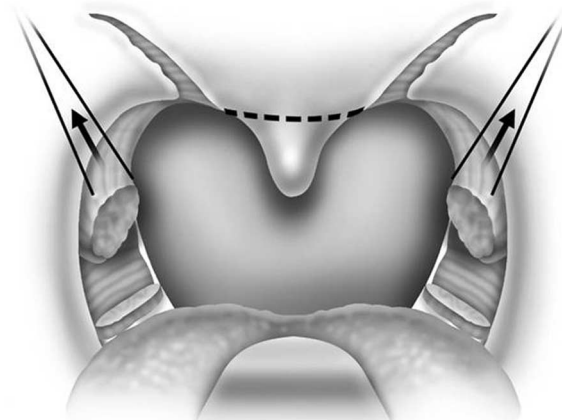


Figure 5 Vicryl sutures used to hitch up the palatopharyngeus muscle to the soft palate muscles superolaterally.

was 42.1 years (range, 24-47 years), and the mean BMI was 28.7 kg/m² (range, 21.7-29.8 kg/m²). The mean preoperative apnea-hypopnea index (AHI) for the entire group improved from 42.3 ± 17.1 to 19.2 ± 12.0 postoperatively with a mean follow-up of 6.5 months. The AHI improved from 44.2 ± 10.2 to 12.0 ± 6.6 (*P* < 0.005) (see Fig. 1) following ESP and from 38.1 ± 6.46 to 19.6 ± 7.9 in the UPPP group (*P* < 0.005) (see Fig. 2). Mean change was 32.2 ± 8.4 in the ESP group and 18.5 ± 7.6 in the UPPP group. Lowest oxygen saturation improved similarly from 78.4 ± 8.52% to 85.2 ± 5.1% in the ESP group (*P* = 0.003) and from 75.1 ± 5.9% to 86.6 ± 2.2% in the UPPP group (*P* < 0.005) (Tables 1 and 2). Selecting an arbitrary threshold of a 50% reduction in AHI and AHI less than 20, success was 82.6% in ESP compared with 68.1% in UPPP (*P* < 0.05). Of great interest, when selecting an arbitrary threshold of a 50% reduction in AHI and AHI less than 15, the ESP success rate was 78.2%, compared with that of the

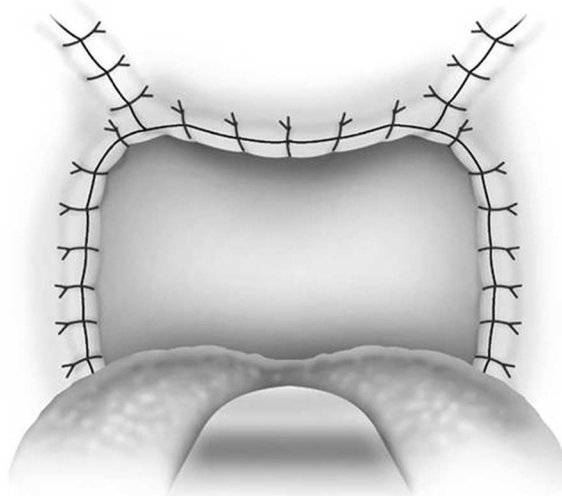


Figure 6 Closure of the palatal incisions.

Table 1
Preoperative and postoperative AHI results of ESP and UPPP with success rate at AHI 50% reduction and <20

	ESP	UPPP
Preoperative AHI	44.2 ± 10.2	38.1 ± 6.6
Postoperative AHI	12.0 ± 6.6	19.6 ± 7.9
P value	<0.005	<0.05
Success rate	82.60%	68.10%
AHI reduction 50% and <20		

UPPP group at only 45.5% ($P < 0.005$) (Table 3). Postoperative endoscopic findings also demonstrated significant reduction of lateral pharyngeal wall collapse in the ESP group, with most patients having only minimal lateral wall movements on Muller’s maneuver postoperatively. All patients in the ESP group had minimal lateral pharyngeal wall collapse noted on Muller’s maneuver, with an average collapse grade of 1.4, not exceeding 50% collapse. This was not the case in the UPPP group, with some patients still having significant lateral pharyngeal wall collapse noted on Muller’s maneuver, postoperatively.

There were no significant complications in either group. All patients started soft diet consumption on the first postoperative day. There was no significant difference in the use of narcotics or pain relief postoperatively in the two groups, and there was no long-term dysphagia or voice change.

DISCUSSION

Cahali¹ described the lateral pharyngoplasty technique in 10 patients with moderate to severe OSA, who had mainly lateral pharyngeal wall collapse noted on clinical endoscopic examination. He showed very promising results in these 10 patients.¹ All 10 patients had improvements in their AHI, with a mean of 45.8, reducing to 15.2 ($P = 0.009$), postoperatively, with a mean follow-up of 8 months. Apnea index also improved with a reduction from a mean of 22.4 to 4.8 ($P = 0.005$). There were, however, significant swal-

Table 2
Preoperative and postoperative AHI results of ESP and UPPP with success rate at AHI 50% reduction and <15

	ESP	UPPP
Preoperative AHI	44.2 ± 10.2	38.1 ± 6.6
Postoperative AHI	12.0 ± 6.6	19.6 ± 7.9
P value	<0.005	<0.05
Success rate	78.20%	45.50%
AHI reduction 50% and <15		

Table 3
Preoperative and postoperative LSAT results of ESP and UPPP with mean change of AHI of each procedure

	ESP	UPPP
Preoperative LSAT	78.4 ± 8.52%	75.1 ± 5.9%
Postoperative LSAT	85.2 ± 5.1%	86.6 ± 2.2%
P value	0.003	<0.005
Mean AHI change	32.2 ± 8.4	18.5 ± 7.6

lowing problems in all 10 patients who underwent this procedure. All patients had dysphagia; this ranged from 8 days to 70 days postoperatively (mean, 20.4 days). One patient had persistent velopharyngeal insufficiency for up to 6 weeks. Another patient had a permanent lost of taste to chocolate for 6 months. Cahali et al⁹ compared this lateral pharyngoplasty technique with the traditional UPPP in 27 patients with OSA. All 15 patients who underwent the lateral pharyngoplasty achieved significant reduction in excessive daytime sleepiness, AHI, and AI. There were also improvement in the rapid eye movement sleep percentage and morning headaches in patients who had the lateral pharyngoplasty, compared with those who underwent the traditional UPPP. They concluded that patients who underwent the lateral pharyngoplasty technique had better clinical and polysomnographic results.

This new technique of ESP was conceived and modified from the Orticochea procedure and the lateral pharyngoplasty. The principle of this technique is to isolate the palatopharyngeus muscle (the main part of the lateral pharyngeal wall bulk) and rotate this muscle superoanterolaterally, to create the lateral wall tension and remove the bulk of the lateral pharyngeal walls. The key is to not completely isolate the muscle into a tube and rotate it; instead, part of its fibrous attachment to the superior pharyngeal constrictor muscle is maintained, so as to create the necessary tension and pull superoanterolaterally. A complete or partial uvulectomy is performed together with this procedure.

The AHI improved from 44.2 ± 10.2 to 12.0 ± 6.6 ($P < 0.005$) following ESP and from 38.1 ± 6.46 to 19.6 ± 7.9 in the UPPP group ($P < 0.005$). The data showed that the patients in the ESP group had more severe OSA compared to the UPPP group. Despite this difference, the mean change was 32.2 ± 8.4 in the ESP group and 18.5 ± 7.6 in the UPPP group. There were also similar impressive results in the lowest oxygen saturation postoperatively.

The data from this small prospective randomized series of 45 patients suggest that the ESP may offer benefit over traditional methods of UPPP in a selected group of OSA patients with small tonsils, Friedman stage II or III, and lateral pharyngeal wall collapse noted on endoscopic examination. Patient selection is an important key to success for most surgical procedures, including this procedure.

CONCLUSION

The ESP is useful and effective in patients with small tonsils, Friedman stage II or III, and lateral pharyngeal wall collapse noted on endoscopic examination. This procedure is simple to perform, has promising results, is anatomically sound, and has minimal complications.⁸

REFERENCES

1. Cahali MB. Lateral pharyngoplasty: a new treatment for OSAHS. *Laryngoscope* 2003;113:1961–8.
2. Borowiecki BD, Sassin JF. Surgical treatment of sleep apnoea. *Arch Otolaryngol* 1983;109:506–12.
3. Terris DJ, Hanasono MM, Liu YC. Reliability of the Muller maneuver and its association with sleep-disordered breathing. *Laryngoscope* 2000; 110:1819–23.

4. Remmers JE, De Groot WJ, Sauerland EK, et al. Pathogenesis of upper airway occlusion during sleep. *J Appl Physiol* 1978;44:931–8.
5. Schwab RJ, Gefter WB, Hoffman EA, et al. Dynamic upper airway imaging during awake respiration in normal subjects and patients with sleep disordered breathing. *Am Rev Respir Dis* 1993;148:1385–400.
6. Orticochea M. Construction of a dynamic muscle sphincter in cleft palates. *Plast Reconstr Surg* 1968;41:323–27.
7. Christel SR, Georges B, Christel D, et al. Sphincter pharyngoplasty as a treatment of velopharyngeal incompetence in young people. *Chest* 2004;125:864–71.
8. Schwab RJ, Gupta KB, Gefter WB, et al. Upper airway and soft tissue anatomy in normal subjects and patients with sleep disordered breathing: significance of the lateral pharyngeal walls. *Am J Respir Crit Care Med* 1995;152:1673–89.
9. Cahali MB, Formigoni GG, Gebrim EM, et al. Lateral pharyngoplasty versus uvulopalatopharyngoplasty: a clinical, polysomnographic and computed tomography measurement comparison. *Sleep* 2004;27: 844–6.

UNCORRECTED PROOF

62
63
64
65
66
67
68
69
70
71
72
73
74
75
76
77
78
79
80
81
82
83
84
85
86
87
88
89
90
91
92
93
94
95
96
97
98
99
100
101
102
103
104
105
106
107
108
109
110
111
112
113
114
115

AUTHOR QUERIES

AUTHOR PLEASE ANSWER ALL QUERIES

1

AQ1— Are all oxygen saturation values given in percent?

AQ2— Is use of “them” clear?
